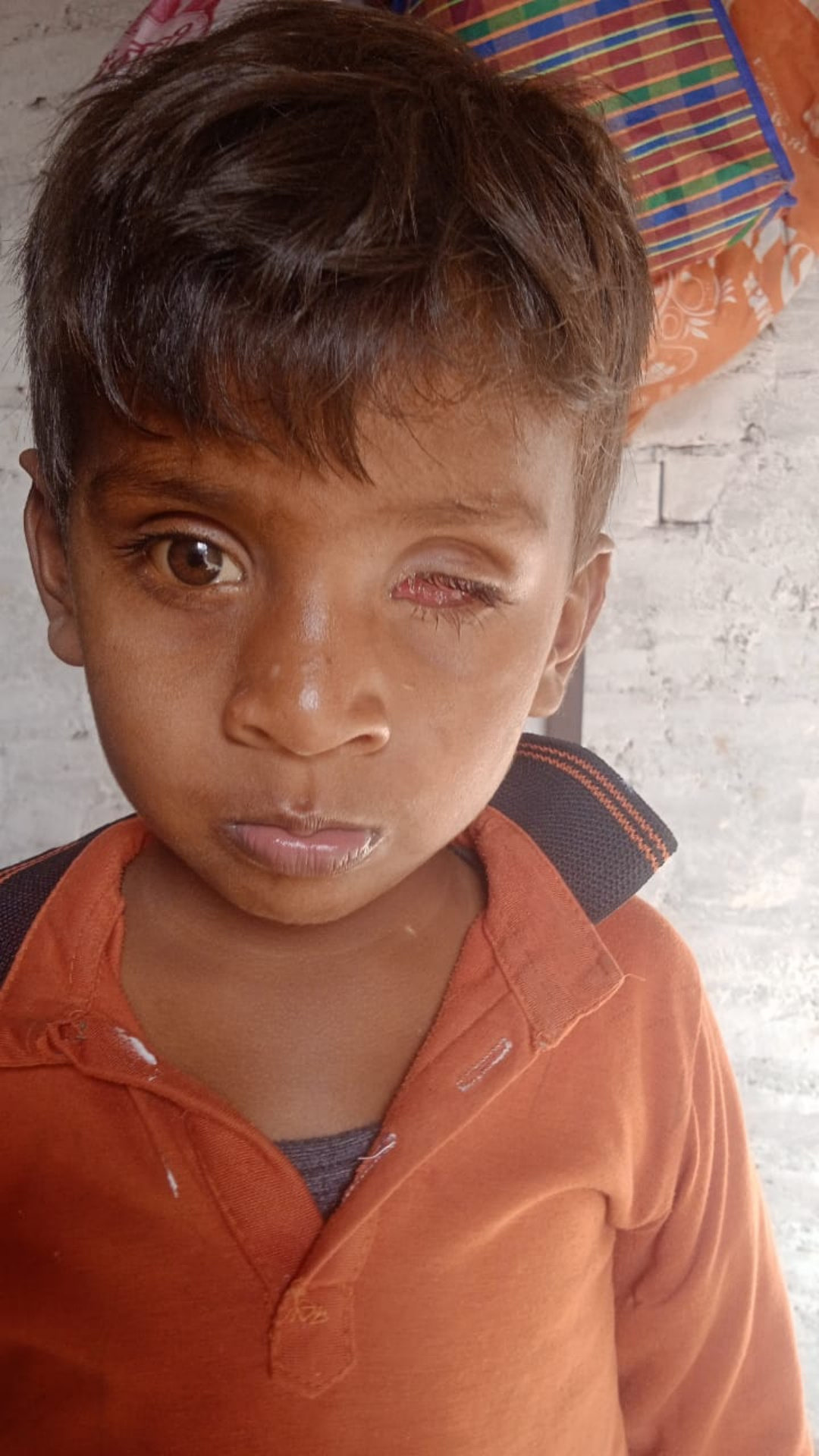



CNC
60

M. Singh
Neha

विकिरण नैदानिक विभाग
अ० भा० आ० सं०, नई दिल्ली-११००२६
DEPARTMENT OF RADIODIAGNOSIS
A.I.I.M.S., NEW DELHI - 110029

PLAIN X-RAY/CONTRAST STUDIES REQUISITION FORM

Name: Nisat Age/Sex: 34 Male Ref. Deptt./Unit: Q Date: 21/2/24

Indoor (Bed No.) / Outdoor / Casualty: 118 UHID No.: 105245352 LMP:

Examination Required :

Clinical History and Examination :

Date: 21/2/24
Time: 11 AM
Neha

C10 B12 Familial RB
↓
2D Echo Holo

Clinical / Working Diagnosis :

anticoagulant exposure
related cardiomyopathy

Blood Urea / S. Creatinine :
Any h / o allergy or asthma :
(for IVU patients only) :

Signature of Referring Physician / Date :
Nisat

Consent :

I hereby give consent for the performance of any diagnostic or therapeutic radiological procedure with or without the use of contrast injection and / or sedation. The associated complications and risks have been explained to me.

Signature of Patient / Date : _____

Your appointment is on : _____ Room No. : _____
Time Slot : 8:30 9:00 9:30 10:00 10:30 11:00 11:30 12:00 12:30

X-Ray No. : _____ Size / No. of Films _____

Date : _____ Kvp/mAS: _____

Sign. of Radiographer : _____

P.T


112124

- details in PUSC file
- TIS CBC & peripheral smear

SEIKFT IHTT
 visual marks
 Vitamin D
 cat11r0431A2P
 urine AIM



- 2D Echo @ end of completion of B fib every 5yrs
- psychological and neurodevelopment assessment
(Riyaji)
- flu & immunization to be resumed in May 24
- ENT flu for BERA (hearing assessment)
C? carboplatin related toxicity
- Ophthalmology flu for implant related complications
- MAS Surveillance every 6 months upto 7yrs age for trilateral RB
- Enrollment in blind schools
- antenatal screening flu for next pregnancy



7/12/2023

Familyial RE

EVA ↓ DR somit 1 DR Praxia
PR 3 resp

Family Hx

⊕

Ⓡ enucleated - gp D → 6/12/22

Ⓛ active gp D LA

Post 6 cycles VEV HD = last 2/5/21

+
7 cycles augmented last = 2/2/22

+
3 VT → 19/4/22
14/5/22
25/6/22

2 Intransit. Topotecan Ⓛ : 12/4/22
25/8/22

3. periocular Ⓡ Ⓡ 6/8/21

BE = 29/7/22

Ⓛ : 2/12/22

ZAC Ⓡ 11/3/22 = M + T

Ⓛ 10/4/23 Ⓛ M + T + CR

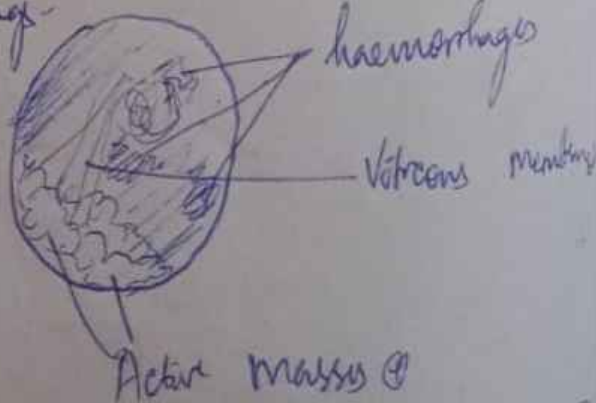28/8/23 ∴ Ⓛ JAC 3 days

Ⓛ = 9/11/23

Ⓛ BE

multiple TTT

EVA findings



25/5/23

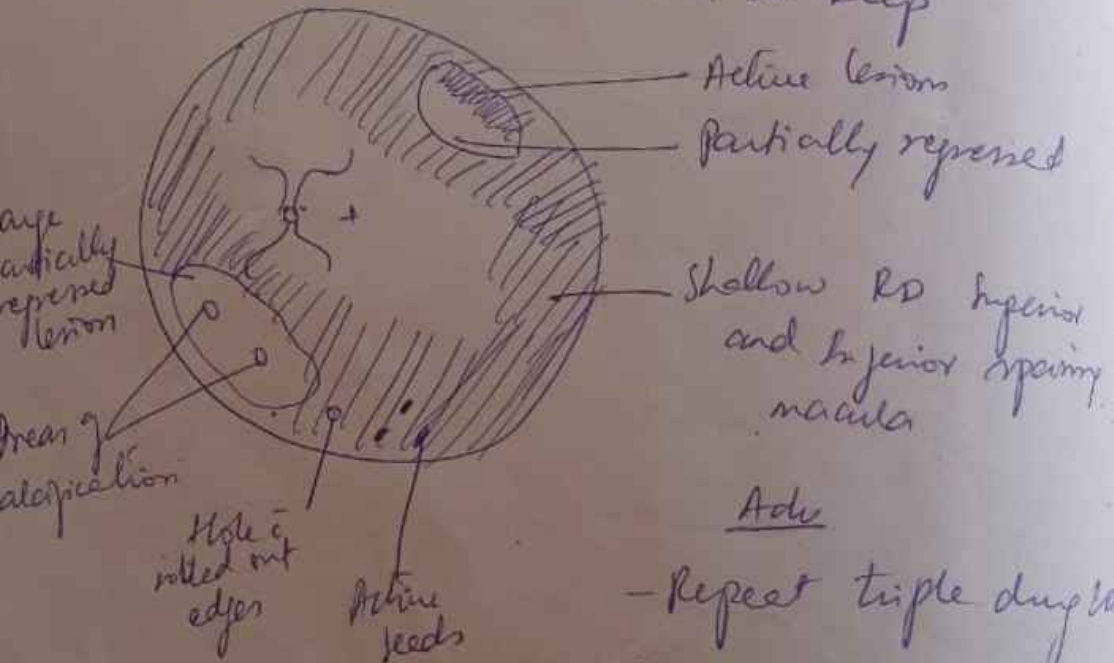
① Intravascular

Melphalen ①

26/5/23

Day

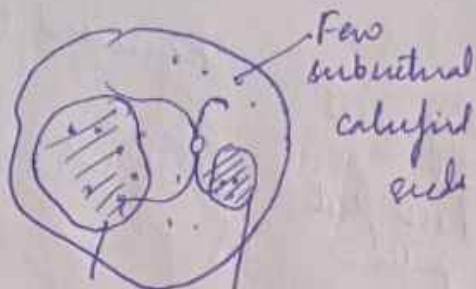
Caudry wa - ① C1/9 @ 80cm
EVA done by Dr. N. Lomni & Dr. Deep



Adv

- Repeat triple drug box
- PTT of active lesion done
- Power - 360 mW
- Duration - 8000ms
- Repeat Interval = 50
- Spots - 40

3/9/21



Mixed type of mass -
few amount of caliciferous



Mixed type
E caliciferous
cells.

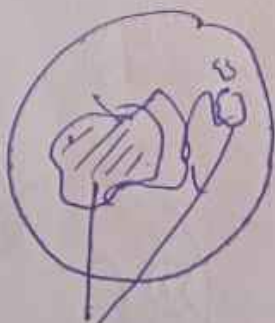BIE regressing pattern

↓

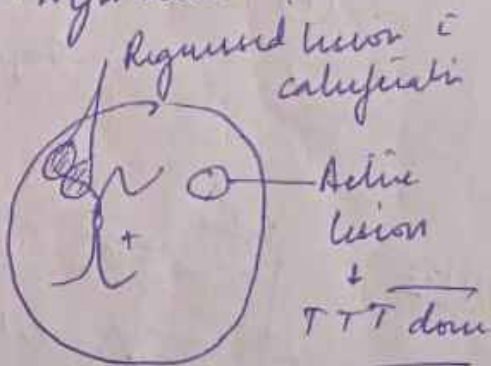
2 Chemo cycles advised

- 29/9/21 Cyto phosphamide + doxorubicin
 - 25/10/21 - High dose

5/11/21



Regressed
lesion & calcification
Total RD:



- 18/11/21
 - 11/12/21 } Augmented high dose chemo



भारत सरकार

Government of India




रिंकी देवी

Rinki Devi

जन्म तिथि / DOB : 01/01/1995

महिला / FEMALE



9369 6640 8143

मेरा आधार, मेरी पहचान



भारतीय विशिष्ट पहचान प्राधिकरण

Unique Identification Authority of India

पता:

W/O: संजय कुमार, भाकरी अहिवासी, कोल, भाकरी
अहिवासी, अलीगढ़, उत्तर प्रदेश - 202002

Address:

W/O: Sanjay Kumar, bhakari ahvasi, koll,
Bhakari Ahivasi, Aligarh, Uttar Pradesh -
202002



9369 6640 8143



1947



help@uidai.gov.in



www.uidai.gov.in